

Brief Reports

Dopa-Responsive Dystonia and Early-Onset Parkinson's Disease in a Patient With GTP Cyclohydrolase I Deficiency?

Lena Elisabeth Hjermland, PhD, MD,^{1,2*}
Lis Gitte Johannsen, MD,³ Nenad Blau, PhD,⁴
Ron Allan Wevers, PhD,⁵
Christoph-Burkhard Lucking, MD,⁶
Jens Michael Hertz, MD,⁷ Lars Friberg, PhD,⁸
Lisbeth Regeur, MD,⁹ Jørgen Erik Nielsen, PhD,^{1,2}
and Sven Asger Sørensen, PhD¹

¹Department of Medical Genetics, The Panum Institute, University of Copenhagen, Copenhagen, Denmark;

²Department of Neurology, Rigshospitalet, Copenhagen, Denmark; ³Department of Neurology, University Hospital of Odense, Denmark; ⁴Division of Clinical Chemistry and Biochemistry, University Children's Hospital, Zurich, Switzerland; ⁵Laboratory of Pediatrics and Neurology, Institute of Neurology, University Hospital Nijmegen, the Netherlands; ⁶Neurological Clinic, Ludwig-Maximilians-Universität München (LMU), München, Germany;

⁷Department of Clinical Genetics, Aarhus University Hospital, Denmark; ⁸Department of Clinical Physiology and Nuclear Medicine, Bispebjerg Hospital, University Hospital of Copenhagen, Copenhagen, Denmark; ⁹Department of Neurology, Bispebjerg Hospital, University Hospital of Copenhagen, Copenhagen, Denmark

Abstract: We describe a patient with a combination of dystonic and parkinsonian signs. Paraclinical studies revealed a mutation in the GTP cyclohydrolase I gene (*GCHI*) and a decrease in [¹²³I]-N- ω -fluoropropyl-2 β -carbomethoxy-3 β -(4-iodophenyl) nortropane (¹²³I-FP-CIT) binding ratios indicative of Parkinson's disease. We conclude that the patient probably suffers from a variant of dopa-responsive dystonia (DRD) or two separate movement disorders, normally considered to be differential diagnoses, DRD and early-onset Parkinson's disease with resulting difficulties concerning treatment and prognosis. © 2006 Movement Disorder Society

*Correspondence to: Lena E. Hjermland, Department of Medical Genetics, 24-4, IMBG, The Panum Institute, Blegdamsvej 3, DK-2200 Copenhagen N, Denmark. E-mail: lena@imbg.ku.dk

Received 10 December 2004; Revised 19 June 2005; Accepted 23 June 2005

Published online 2 November 2005 in Wiley InterScience (www.interscience.wiley.com). DOI: 10.1002/mds.20773

Key words: dopa-responsive dystonia; early-onset Parkinson's disease; GTP cyclohydrolase I gene; ¹²³I-FP-CIT-SPECT scan

Dopa-responsive dystonia (DRD) and early-onset Parkinson's disease (EOPD) are clinically difficult to differentiate, but clarification of the diagnosis is important for the treatment, prognosis, and genetic counseling of patients and families. Fortunately, it is possible to perform mutation analyses for DRD as well as EOPD, although the locus and allele heterogeneity of both diseases make routine analysis laborious. Mutations in the GTP cyclohydrolase I gene (*GCHI*) are the most common cause of DRD, whereas mutations in the parkin gene (*PARK2*) are the most common of the known monogenic forms of idiopathic Parkinson's disease (PD).

Here, we present a patient with a mutation in *GCHI*, which we initially thought gave the final diagnosis: DRD. However, further examinations also indicated a possible second diagnosis: EOPD. It was concluded that the patient might suffer from both disorders, which gave problems concerning the treatment, prognosis, and genetic counseling.

CASE REPORT

The patient is the second child of healthy and nonconsanguineous parents. He is a 38-year-old Danish man with insignificant symptoms of the legs in childhood, including the feeling of the malleoli colliding while walking, and he was unable to sit with legs crossed. Nonetheless, he was able to play football. In 1994, at the age of 28 years, he developed increasing problems using the left hand. The hand and fingers became slow and stiff, and he felt intermittent cramps, especially when using the hand. At the same time, he got burning pain between the scapulae. Shortly after, his head started bending backward and turning to the right. Gradually, he had to work less than usual as a fulltime cook and waiter, and 1 year later, he had to stop work.

From January 1996 he had problems using both hands, constant backward bending in neck and back, and pain most of the day. The course of his now generalized dystonia fluctuated greatly, but he always felt improvement after rest.

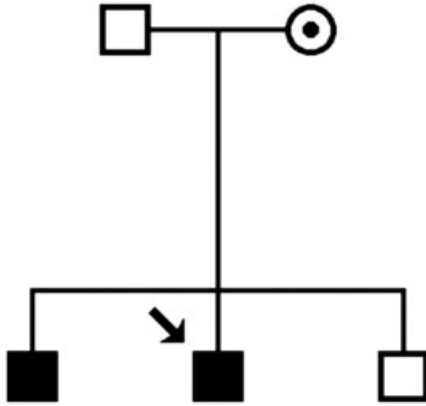


FIG. 1. Pedigree of the family. The arrow points at the index patient. Filled squares indicate affected male members. The circle with a dot indicates an unaffected female carrier.

In 1995, secondary dystonia was excluded by clinical, biochemical, and neurophysiological examination and a magnetic resonance imaging (MRI) scan of the brain.

He was treated with intramuscular injections of botulinum toxin and oral oxazepam, benzhexol, baclofen, and tetrabenazine with unsatisfactory results and side effects from tetrabenazine. Physical therapy (massage) had an excellent but short-lasting effect.

In 1999, when he was 33 years old, levodopa with carbidopa was added to baclofen with good effect on handwriting, gait, general stiffness, and tremor. After nearly 2 years he began to have increasing dyskinesia, while taking 350 mg L-dopa a day. When the dose was reduced, he immediately felt stiff and slow. Selegiline, entacapone, and different dopamine agonists were tried to decrease the L-dopa dose. However, the patient could not tolerate the feeling of stiffness and pain, especially in his back, and he preferred the intermittent hyperkinesia during the day.

In Spring 2003, he has been without L-dopa treatment for several months and is again treated with selegiline and a dopamine agonist, with less benefit than during previous L-dopa treatment. He still has excellent benefit from physical therapy, and his symptoms fluctuate, with benefit after sleep and rest. He has retrocollis, dystonia in both arms and legs, and action tremor, all most severe on the left side.

His parents and two brothers were examined clinically, and blood samples were collected. The index patient is the only one symptomatically affected in the family, but at clinical examination, his older brother had writer's cramp on the right side and action tremor in both hands (Fig. 1).

MATERIALS AND METHODS

Molecular Genetic Studies Concerning DRD

Genomic DNA from the patient, his parents, and two brothers were extracted from white blood cells with Puregene DNA isolation kit D-50K. Informed consent was obtained from each individual. The promotor region and six exons of *GCHI* were amplified and sequenced using primer pairs as previously reported.¹

Biochemical Studies

The activity of the enzyme GTPCH was measured in cultured cytokine-stimulated dermal fibroblasts as described earlier.² In the cerebrospinal fluid (CSF), the neurotransmitter metabolites, homovanillic acid (HVA), and 5-hydroxyindoleacetic acid (5-HIAA) were measured as described previously.³ The patient was on treatment with L-dopa at the time of lumbar puncture.

Neuroradiological Studies

In 2001 and 2002, single photon emission computerized tomography (SPECT) of the presynaptic dopamine transporters (DAT receptors) and of the postsynaptic dopamine receptors were performed with a Marconi PRISM 3000XP triple-head gamma camera with ultra-high-resolution, fan-beam collimators. The ligands used were [¹²³I]-N- ω -fluoropropyl-2 β -carbomethoxy-3 β -(4-iodophenyl) nortropine (¹²³I-FP-CIT) and [¹²³I]-(*S*)-2-hydroxy-3-iodo-6-methoxy-N-[(1-ethyl-2-pyrrolidinyl)methyl]-benzamide (¹²³I-IBZM), respectively. SPECT acquisitions were performed using a 360-degree orbit for each collimator.

Molecular Genetic Studies Concerning EOPD

Exon rearrangements of *PARK2* were analyzed using a semiquantitative multiplex polymerase chain reaction (PCR) protocol described elsewhere.⁴ Single-stranded conformational polymorphism analysis was used to investigate for point mutations as described earlier.⁵

RESULTS

Molecular Genetic Studies Concerning DRD

A point mutation in exon 5 of *GCHI* (595C>T, P199S) was detected in DNA from the patient, his older brother, and his unaffected mother. The mutation has not been earlier reported in patients with DRD (BIOMDB Database, online at <http://www.bh4.org/biomdb.html>) and was not encountered in 360 chromosomes from Danish controls.

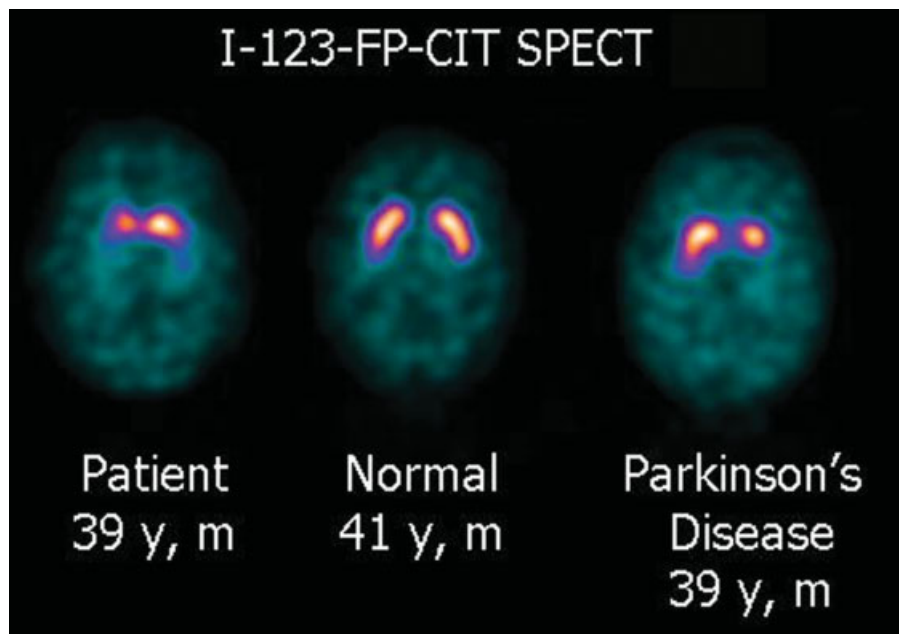


FIG. 2. [^{123}I]-N- ω -fluoropropyl-2 β -carbomethoxy-3 β -(4-iodophenyl) nortropine single photon emission computerized tomography (^{123}I -FP-CIT SPECT) of the patient, an age-matched nonaffected control, and an age-matched patient with idiopathic Parkinson's disease. y, years of age; m, male.

Biochemical Studies

GTPCH activity in the fibroblasts was very low (0.11 $\mu\text{U}/\text{mg}$ protein; controls 1.4–6.5 $\mu\text{U}/\text{mg}$ protein), whereas neurotransmitter metabolites in CSF were detected normal, probably due to L-dopa treatment (data not shown). Neopterin and biopterin were not measured in the initial CSF, and the patient denied a second lumbar puncture.

Neuroradiological Studies

A decrease in ^{123}I -FP-CIT binding ratios was seen in the patient in comparison with age-matched controls in all regions of interest, striatum, putamen, and the caudate region, suggesting the characteristic nigrostriatal dopaminergic degeneration seen in patients with EOPD as well as PD in general (Fig. 2). The ^{123}I -IBZM uptake was normal.

Molecular Genetic Studies Concerning EOPD

No mutation was encountered in *PARK2*.

DISCUSSION

The patient reported here showed signs and symptoms consistent with DRD from the age of 28 and, from the age of 35, side effects consistent with EOPD. The detection of a single base change in *GCHI* supports the clinical diagnosis of DRD. Tassin and colleagues⁶ reported a missense mutation in the same codon (P199L) as the present described in a family with typical DRD. In this family, the normally occurring hydrophilic amino

acid proline was changed to the hydrophobic amino acid leucine, whereas the mutation in the here-reported family resulted in a change to another hydrophilic amino acid, serine. Furthermore, the activity of GTPCH in the fibroblasts was reduced as expected in DRD.² But the neurotransmitter metabolite CSF-HVA was in the normal range, in contrast to the usual decrease detected in DRD⁷ and in EOPD as well as generally in PD, which may be due to influence of artificial L-dopa in his central nervous system.

The same mutation in *GCHI* was found in DNA from his older brother with writer's cramp and the unaffected mother.

No mutation was encountered in *PARK2*, but this finding does not exclude EOPD.⁴ In favor of EOPD is the decreased ^{123}I -FP-CIT binding ratio, which is characteristic in EOPD but not in DRD, as the progressive loss of nigral cells in EOPD results in decreased presynaptic D1 receptor uptake.⁸ In patients with DRD, which is not a neurodegenerative disorder, the scans are without decreased presynaptic D1 receptor uptake, explained by a normal dopa uptake, decarboxylation of dopa, and storage of dopamine in the nigrostriatal dopaminergic terminals.^{9–11} However, imaging is just indicative, rather than diagnostic, of nigral cell loss.

Additional evidence in favor of EOPD is that the patient developed dyskinesia after 2 years of L-dopa treatment. Such dyskinesia is usually seen in EOPD but not DRD. An important difference between DRD and EOPD is the long-term L-dopa benefit without dopa-

related complications in DRD and the L-dopa-induced dyskinesias in EOPD.^{12,13} Dopa-related complications, however, occasionally are reported in patients with DRD.^{6,13,14.}

Kikuchi and coworkers also reported on a man with DRD and reduced ligand uptake (¹⁸F-dopa positron emission tomography [¹⁸F-dopa PET]), but the onset of symptoms was later, the side effects appeared much later, and the PET scan was performed at 54 years of age, an age when Parkinsonism of other etiologies is more common.¹⁵

The molecular genetic and the biochemical findings show definitely that the patient suffers from DRD. But the neuroimaging findings suggest that the patient may have EOPD as well and consequently either has a rare variant phenotype of DRD or perhaps two movement disorders.

Imaging data of the affected brother with the DRD mutation might help differentiating the image of his possible DRD from the decreased binding presumably caused by EOPD in the index patient. Also, imaging data of the nonaffected mother with the same mutation in *GCHI* would be of interest; but the brother and mother declined a SPECT scan.

Recently, polymorphisms of *PARK2* on each allele have been suggested to alter the clinical presentation of a patient with a point mutation in *GCHI*. But findings on an ¹⁸F-dopa PET scan of this patient were within the normal limits.¹⁶

Here, the conclusion is that the reported patient most likely has variant DRD and maybe also EOPD and symptoms from both diseases. The inheritance of DRD is autosomal dominant, whereas EOPD most often is an autosomal recessive disease. The genetic counseling depends on an exact diagnosis to estimate the risks and consequences for the relatives. In the present case, the risk of his prospective children is increased concerning DRD but cannot be estimated regarding EOPD. A family history may be difficult to interpret in both diseases, because the low penetrance of the DRD gene may resemble recessive inheritance. Furthermore, EOPD can be sporadic and autosomal dominant inherited as well. This case illustrates the complexity of diagnosing inherited movement disorders as well as the importance to establish a correct diagnosis.

REFERENCES

1. Bandmann O, Valente EM, Holmans P, et al. Dopa-responsive dystonia: a clinical and molecular genetic study. *Ann Neurol* 1998;44:649–656.
2. Bonafé L, Thöny B, Leimbacher W, et al. Diagnosis of dopa-responsive dystonia and other tetrahydrobiopterin disorders by study of biopterin metabolism in fibroblasts. *Clin Chem* 2001;47:477–485.
3. Bräutigam C, Wevers RA, Jansen RJT, et al. Biochemical hallmarks of tyrosine hydroxylase deficiency. *Clin Chem* 1998;44:1897–1904.
4. Lücking CB, Dürr A, Bonifati V, et al. Association between early-onset Parkinson's disease and mutations in the *parkin* gene. *N Engl J Med* 2000;342:1560–1567.
5. Hertz JM, Ostergaard K, Juncker I, et al. Mutation analysis of the Parkin (*PARK2*), the Tyrosine Hydroxylase (*TH*), and the GTP Cyclohydrolase I (*GCHI*) genes in a Danish population of early-onset Parkinson's Disease. Submitted 2004.
6. Tassin J, Dürr A, Bonnet A-M, et al. Levodopa-responsive dystonia GTP cyclohydrolase I or parkin mutations? *Brain* 2000;123:1112–1121.
7. Blau N, Bonafé L, Thöny B. Tetrahydrobiopterin deficiencies without hyperphenylalaninemia: diagnosis and genetics of dopa-responsive dystonia and sepiapterin reductase deficiency. *Mol Genet Metab* 2001;74:172–185.
8. Khan NL, Brooks DJ, Pavese N, et al. Progression of nigrostriatal dysfunction in a *parkin* kindred: an [¹⁸F]dopa PET and clinical study. *Brain* 2002;125:2248–2256.
9. Snow BJ, Nygaard TG, Takahashi H, Calne DB. Positron emission tomographic studies of dopa-responsive dystonia and early-onset idiopathic parkinsonism. *Ann Neurol* 1993;34:733–738.
10. Furukawa Y, Mizuno Y, Narabayashi H. Early-onset parkinsonism with dystonia. Clinical and biochemical differences from hereditary progressive dystonia or dopa-responsive dystonia. *Adv Neurol* 1996;69:327–337.
11. Huang CC, Yen TC, Weng YH, Lu CS. Normal dopamine transporter binding in dopa responsive dystonia. *J Neurol* 2002;249:1016–1020.
12. Jeon BS, Jeong J-M, Park S-S, et al. Dopamine transporter density measured by [¹²³I]β-CIT single-photon emission computed tomography is normal in dopa-responsive dystonia. *Ann Neurol* 1998;43:792–800.
13. Nygaard TG, Marsden CD, Fahn S. Dopa-responsive dystonia: long-term treatment response and prognosis. *Neurology* 1991;41:174–181.
14. de la Fuente-Fernandez R. Drug-induced motor complications in dopa-responsive dystonia: implications for the pathogenesis of dyskinesias and motor fluctuations. *Clin Neuropharmacol* 1999;22:216–219.
15. Kikuchi A, Takeda A, Fujihara K, et al. Arg(184)His mutant GTP cyclohydrolase I, causing recessive hyperphenylalaninemia, is responsible for dopa-responsive dystonia with parkinsonism: a case report. *Mov Disord* 2004;19:590–593.
16. Postuma RB, Furukawa Y, Rogaeva E, et al. Dopa-responsive dystonia presenting with prominent isolated bilateral resting leg tremor: evidence for a role of parkin? *Mov Disord* 2003;18:1070–1072.