

Sepiapterin reductase deficiency: a congenital dopa-responsive motor and cognitive disorder

B. G. R. Neville,^{1,2} R. Parascandolo,³ R. Farrugia⁴ and A. Felice⁴

¹Neurosciences Unit, Institute of Child Health (UCL) and ²Great Ormond Street Hospital, 30 Guilford Street, London, UK, ³Division of Paediatrics, St Luke's Hospital, G'Mangia, Malta and ⁴Laboratory of Molecular Genetics, Department of Physiology and Biochemistry, Faculty of Medicine and Surgery, University of Malta, Msida, Malta

Correspondence to: Professor B. G. R. Neville, The Wolfson Centre, Mecklenburgh Square, London WC1N 2AP, UK
E-mail: b.neville@ich.ucl.ac.uk

This study presents the clinical findings on seven children from Malta (population 385 000). All of them had early motor delay and a significant degree of cognitive impairment. Diurnal variation of the motor impairments was clear in six out of seven of the subjects and oculogyric crises occurred from an early stage also in six out of the seven. Five out of seven had clear evidence of dystonia but the early picture was dominated by hypotonia in five. Two had early Parkinsonian tremor and chorea was seen in four, although in two this was attributable to the use of L-dopa. Three had early bulbar involvement. In all, although minor motor problems persisted, the response to L-dopa was dramatic and there was a need to balance improvement in dystonia against aggravation of chorea. The majority were not able to walk until they were treated. Increased doses of L-dopa were required in hot weather, to which they were sensitive. Despite a good response of improved motor ability and abolition of oculogyric crises, there was no obvious change in cognitive function with learning remaining in the moderate impairment range. This report widens the phenotype of dopa-responsive motor disorders and the range of young children with primary motor delay (cerebral palsy) who need a clinical trial of L-dopa. All of the subjects had the same novel mutation in the tetrahydrobiopterin pathway involving sepiapterin reductase, and no abnormality in the gene encoding guanosine triphosphate cyclohydrolase I. Clinically and molecularly the condition shows autosomal recessive inheritance.

Keywords: cognition; dopa responsive; L-dopa; sepiapterin reductase

Abbreviations: ADGTPCHI = Autosomal dominant guanosine triphosphate cyclohydrolase I; BH₄ = Tetrahydrobiopterin; SR = Sepiapterin reductase

Received September 17, 2004. Revised December 10, 2004. Re- Revised June 21, 2005. Accepted June 28, 2005. Advance Access publication July 27, 2005

Introduction

L-dopa responsive dystonia (Segawa disease) is perhaps the most remarkable neurometabolic disorder in its classical form (Segawa *et al.*, 1976) with normal early development followed by the onset of pure dystonia with diurnal variation and a complete long lasting response to low dose L-dopa. The implication of autosomal dominant GTP cyclohydrolase I (ADGTPCHI) deficiency in this condition came much later, (Ichinose *et al.*, 1994) during which time it became apparent that each of the cardinal points of the diagnosis had exceptions despite having genetic defects within the same pathway and sometimes identical defects by being within the same family. Specifically there are reports of patients with pyramidal signs, with little diurnal variation, of some who need larger doses of L-dopa (Segawa *et al.*, 2003) and also in whom the

response is incomplete and of a congenital onset with early hypotonia (Robinson *et al.*, 1999; Tsirikos *et al.*, 2004). Because this is a treatable disorder this has caused concerns about which children should have a trial of L-dopa. The situation is moving towards a therapeutic trial in most children with an unexplained central motor disorder, but this is not yet a universal practice.

This report is of a group of children from Malta who were given L-dopa as a clinical trial initially because of having an unexplained motor disorder with features that did not closely resemble Segawa disease and showed a dramatic but usually incomplete motor response to L-dopa.

The island of Malta has had many genetic influences, but within its population of 385 000 there are a number of distinct

genetic disorders including GM1 Gangliosidosis (Lenicker *et al.*, 1997) and dihydropterine reductase being the predominant cause of phenylketonuria (Farrugia *et al.*, 2005).

Methods

All patients who had responded to L-dopa, and their families were reviewed and re-examined and blood taken for DNA studies. Detailed genetic studies are reported elsewhere (Farrugia *et al.*, 2005) but are summarized in this manuscript.

Case reports

All patients were treated with Sinamet 110 (L-dopa 100 mg, Carbidopa 10 mg/tablet). The doses used are given in Table 2 as amount of L-dopa/day. Small temporary increases in dosage are given by the families as necessary e.g. in very hot weather.

Patient 1

This boy was examined at the age of 10. His grandfather has Parkinson's disease with tightness of his jaw in the mornings and a poor response to L-dopa. Pregnancy, delivery and neonatal period were normal. He fed normally but had episodes of inconsolable crying. From the age of 6 months it was clear that he was not normal. Although usually floppy, his limbs were sometimes stiff and at times he had a tight jaw. When examined at 10 months he had poor head control, was unable to roll, did not reach and was unable to sit. Proximal tone was reduced and the limbs were rigidly stiff with reduced power and very brisk deep tendon reflexes. He would be active on waking but would become lethargic and weaker after half an hour. He learned to stand holding on at 3–4 years and was making progress, continuing to be better in the mornings but sudden excitement would make him weaker. With an intercurrent chest infection, his assisted walking was lost and he had to use a wheelchair for 4 weeks. His first dose of L-dopa was given in 1997, at the age of 7 years. At that time he was rigidly flexed in the upper limbs with tight fistings and his feet were turned in markedly with signs of a dystonic tetraplegia. His face was symmetrically mask-like with drooping eyelids from the first year. He dribbled and had feeding difficulties with choking from the first year and speech was limited to single words, which were not always intelligible. After the first dose of L-dopa at 7 years, his face developed expressions, he stopped dribbling, waved to people from his chair and he then got up and started walking. He walked holding on for about a month and then was able to walk independently. This was also awkward initially, having never walked independently before. He could eat easily and speak clearly in sentences. From the first year of life he had episodes of his eyes rolling up with significant discomfort lasting for minutes to hours. It would sometimes happen when he was excited and he would appear stiffer particularly round the neck and shoulders in these episodes. Previously, the only way to relieve them was to encourage him to sleep when he would be fine on waking. These happened daily but stopped with the use of L-dopa. However, if he feels his eyes are rolling up a small temporary increase in L-dopa dosage is effective. He can now take long walks and play hockey and run. His early language development and school progress were slow, and despite the motor improvement on treatment he functions at about a 6 year old level at 10 years. At the age of 10 he started to read. When reviewed at 7 years he still had dystonic grimacing movements of the face, mild dystonic posturing of the limbs and

some choreic jerks of the face and limbs, which had not been seen before giving L-dopa. Physical examination at 10 years showed normal eye movements and facial movements but with small irregular jerky movements of the hands and arms which were not stereotyped and regarded as choreic. He had normal muscle tone and strength. His feet showed a valgus hind foot with normal muscle tone. There was no definite dystonia and the tendon reflexes were normal with flexor plantar responses.

In summary, he is a boy with no definite family history of dopa-responsive dystonia who had primary motor delay and a mixture of distal hypertonus and proximal hypotonus with early oculogyric crises, clear evidence later of dystonia with a dramatic response to L-dopa with some persisting chorea and moderate learning difficulties. Until L-dopa was tried, he was regarded as having cerebral palsy.

Patient 2

This girl was examined at 14 years. She has an affected sibling (Patient 3) and her father's brother has a daughter who is also affected (Patient 4). The two affected sisters' 16 year old brother is normal. Pregnancy was normal, as was the delivery. She had a weak cry as a baby and her motor development was always slow. She could only just sit at 1 year. She was reported to be very floppy and without abnormal movements. She was much stronger in the morning than in the evening. From the first year she had episodes of her eyes rolling up, particularly at around 10 a.m., which stayed up for hours and was relieved after a sleep. Her speech was also slow and she made slow progress at school and currently can read at a simple level. Before treatment she was able to walk around six paces across the room indoors but somewhat further if it was the first thing in the morning. She had a crouching, irregular gait, which was not obviously dystonic. She was given her first dose of L-dopa at the age of 10 years 10 months. Initially she was flushed and seemed lethargic but after 8 h there was definite improvement and apparently she could walk normally. Increase in the dose of L-dopa to 100 mg b.d. was accompanied by choreic movements of the face and arms, which stopped after the dose was reduced. When seen at 14 years of age her eye movements were normal; tongue movements were slow; there was mild dystonic posturing of the left hand on reaching; forearm rotational movements were slow, with dystonic posturing more on the left; no choreic movements were seen; walking was effective but slightly irregular, i.e. lacking smooth cadences and consistency; and muscle tone and tendon reflexes were normal. An early symptom was episodic vomiting which stopped when L-dopa was given. From 15 years she developed galactorrhoea secondary to a prolactinoma, which has been treated with bromocriptine.

In summary, she had early motor impairment dominated by hypotonia, with the later appearance of dystonia. She had oculogyric crises from the first year of life and had a dramatic response to L-dopa. She continues to have moderate learning difficulties and has mild dystonia despite the treatment.

Patient 3

This girl is the sister of Patient 2. Pregnancy and perinatal period were normal. She behaved normally at birth with normal feeding. At 1 month her breathing was noticed to be noisy and prolonged episodes of eyes rolling up occurred. She was motor delayed from the first year and did not sit until the age of 2 years. She shuffled on her bottom until the age of 3–4 years and then lost this skill. She never

walked until L-dopa was given. She was stiff with fisting and her feet turning in, in contrast to her sister who was predominantly hypotonic. The eye rolling episodes were initially thought to be seizures, although it was clear that she was awake during the episodes of upgaze in which she was stiff with extension of the neck and spine, and she described the sensation as 'like having a stone in her head' and being unpleasant. She was definitely better in the mornings and when was able to shuffle did so in the morning but not in the afternoon. Her speech was slow using sentences of three words at about the age of 3. She was first given L-dopa at 8½ years. Having been in a wheelchair she learned to walk independently over the next 2 months. Her speech also improved markedly. She was maintained on 100 mg of L-dopa daily, having been choreic on 200 mg. She needed a little more of L-dopa in hot weather. Her behaviour was somewhat disinhibited, contrasting with that of her sister who is quiet and although she concentrates quite well has continued to have moderate learning difficulties. Examination at 11 years showed normal eye movements, slow tongue movements and outstretched hands showed mild dystonic posturing, left more than right with minimal irregular choreic jerks. There was mild dystonia on rotational movements of the forearms, left more than right. She walked well with mild irregular choreic movements of trunk and limbs. Tone was normal. Tendon reflexes were brisk but normal.

In summary she had oculogyric crises and motor delay dominated by hypertonus from the first year of life, she never walked and there was some regression of skills. She had clear diurnal variation. She had a dramatic response to L-dopa and now has only mild cosmetic motor impairment but significant cognitive impairment.

Patient 4

This 8 year old girl was her parents' only child. Her father works as a stone mason and his brother is the father of Patients 2 and 3. The pregnancy was accompanied by some abdominal pain. The delivery was normal after induction. She had very dry skin at birth. Breathing was delayed with meconium-stained liquor but she cried after 3 min. Feeding was difficult with swallowing problems and an obviously stiff tongue. She required tube feeding for the first 24 h and feeding became more difficult from 3 months and food dribbled from the corners of her mouth. She was clearly better in the mornings. From 5½ months she had episodes of her eyes rolling up 3–4 times a week with trunk stiffening and neck extension. She was treated with sodium valproate, without any effect. She sat alone at 3 years of age and never walked until L-dopa was given. No abnormal movements were seen. She used three word sentences by the age of 3 years. When seen at the age of 5 she had mild stiffness of the limbs and proximal hypotonia but no dystonic postures or movements. She was given L-dopa at the age of 5 years 5 months, and she stood up 20 min later and walked 3 weeks later, and had a normal gait after 3 months. She remained moderately cognitively impaired. On examination at 8 years of age eye movements were normal, her face was normal, tongue movements were a little slow, there was very mild slowing of left hand repetitive finger movements, tendon reflexes were brisk but within normal limits without clonus and with flexor plantar responses, and there was no evidence of dystonia.

In summary this 8 year old girl had early motor delay dominated by proximal hypotonia with a little stiffening and early oculogyric crises. Dystonia was never recorded. Her severe motor delay responded dramatically and almost totally to low dose of L-dopa. She has moderate cognitive impairment.

Patient 5

This boy was observed at 5 years. He has an affected brother (Patient 6) but there are no other affected family members. Pregnancy was normal but there was a prolonged labour with meconium-stained liquor. He fed well. At 6 months he was not sitting. He eventually sat alone at 1 year and walked with a springy toe walk, unsteadily at 19 months with difficulties in balancing. Early on, a positive Gower's sign was noted. From 8 months there were daily episodes of prolonged upward eye-rolling relieved by sleep. By parental history he was always stiff with abnormal twisting movements on reaching. Before he was given L-dopa he had fast fleeting jerky movements and his speech was limited to single noises. Excessive sweating was reported. At the age of 4 years 2 months when he was first given L-dopa he spoke in single words an hour afterwards and he rapidly used sentences. Dribbling, which had been present before, ceased, as did his chewing and swallowing difficulties. Before treatment with L-dopa he had had much better functioning in the mornings but would get tired by 10 a.m. His walking, immediately after, was better than at its best after sleep after being given L-dopa. He became able to walk long distances but not with a normal gait. He could write but he held the pencil with a fisted and tight grip, typical of writer's cramp. His school progress was slow. He had not begun to read and had at least mild cognitive delay.

Eye movements were normal, and he had slow alternating tongue movements and mild wandering of the outstretched hands with irregular choreic movements. He had marked difficulty with gesture imitation, indicating a degree of dyspraxia. He had slow alternating movements. His gait showed a lack of smoothness and consistency, and was variable with some dystonic movements but it was effective. There was no abnormality in muscle tone or tendon reflexes.

In summary, this boy had primary motor delay but did manage to walk before the treatment was given. There was clear historical evidence of early dystonia, chorea and oculogyric crises. He had a dramatic response to L-dopa but was left with writer's cramp and mild cognitive delay.

Patient 6

This boy was observed at 11 months and is the brother of Patient 5. A Caesarean section was performed because of the difficulties with the previous pregnancy and his condition was normal at birth with normal feeding. He was normal until 2–3 months of age, when wheezy bronchitis began. He was given Ventolin and a fine tremor of his hands appeared. This was a static rotational Parkinsonian tremor of the forearms and fingers. It occasionally spread to involve the face, trunk and legs. At 3 months he developed extensor hypertonic attacks of the neck and trunk which lasted several minutes without clear vertical eye movements. He was clearly weaker in the evenings with head lag and irritability and crying, and noted to be very floppy both proximally and distally. No twisting or stiffening movements were seen but because of the family history L-dopa was given at 6 months. He began reaching, his tremor disappeared the same day, his head control improved, he sat alone at 9 months, the use of Ventolin could be continued without tremor and he was maintained on L-dopa. At 15 months he sat alone, crawled and pulled to stand. During a chest infection treated by using erythromycin, L-dopa was withdrawn with rapid deterioration. His speech remained very little with some simple understanding at a labelling level. He, like his brother, had excessive sweating. There were no signs of dystonic postures or movements.

In summary, this boy had a very early onset of Parkinsonian tremor with episodic extensor spasms, motor delay dominated by hypotonia and a dramatic but incomplete response to L-dopa at 6 months of age and has evidence of cognitive delay.

Patient 7

This boy was observed for the review at 3 years of age. He had a somewhat complicated family history, with a paternal grandfather who first walked at 7 years of age and worked as a stone quarrier but was very slow at school, and a father who shuffled and then walked at 3 years of age who also had slow school progress and also worked in a stonequarry. The pregnancy and birth were normal. He had transient mild neonatal jaundice. He fed well, but at 2 months stiffness and intermittent pronator/posturing of the arms with finger extension and a rotational Parkinsonian-type tremor of the forearm and fingers were noted at rest. He also developed episodes of prolonged upward eye rolling with crying, and his shoulders stiffened and neck extended in these episodes. They were relieved by sleeping. He could not sit and had head lag. He started L-dopa at 11 months. He could sit immediately. His tremor stopped and his arms appeared to function normally. He has been maintained on L-dopa and can run. His speech at 3 years was limited to single words. He has no neurological signs and a normal gait.

In summary he is a boy with primary motor delay, very early dystonia, Parkinsonian tremor and oculogyric crises with a full motor response to low dose L-dopa but with signs of moderate cognitive delay. The clinical findings in this group of patients are summarized in the Table 1.

All presented with primary motor delay and cognitive impairment. Six out of seven had oculogyric crises, in some accompanied by retrocollis, and the remaining Patient 6 had suspicious episodic extensor stiffening and was treated very early, at the age of 6 months. Three had early bulbar involvement. Although five out of seven had evidence of dystonia the early presentation was dominated by hypotonia and apparent weakness in five. Two had a very early Parkinsonian tremor and four had chorea: two before L-dopa was given and two after. All showed a degree of diurnal variation with sleep providing a restoration of some motor skills and a temporary remission in oculogyric crises. All of them had a dramatic motor response to L-dopa but with usually minor motor manifestations of chorea and dystonia persisting, and in some L-dopa tended to aggravate the chorea. All but one only walked independently after treatment with L-dopa but in two the treatment was started before the age of 1 year. The ocular manifestations and Parkinsonian tremor responded totally to L-dopa. There was no obvious change in cognitive function although improvements in motor, including

bulbar, function allowed the children to perform better but never to achieve normal developmental or educational progress.

Blood aromatic amino acid levels were normal.

Molecular biology

Re-sequencing of the GTPCH I gene, which is classically associated with Segawa disease, failed to reveal any gene defect among any of the seven probands. However, sequencing of the SPR gene in the tetrahydrobiopterin (BH₄) recycling pathway showed that all the seven probands were homozygotes for a new mutation, i.e. gSPR, IVS-II and 2G (Farrugia *et al.*, 2005). All their parents were heterozygotes. The transcription effects of mutations, such as this one that occur in or close to the intron–exon junction, have been best quantified among the globin genes (Marwan *et al.*, 1999). When the mutation occurs in the first 2–3 nucleotides of the intron, all protein expression is suppressed because splicing is severely impaired. The new mutation in sepiapterin reductase (SR) is likely to impair transcription processing and cause deficiencies in sepiapterin reductase, thus decreasing levels of BH₄ and dopa. The site of action of sepiapterin reductase is shown in Fig. 1.

Discussion

Although it has some resemblances to Segawa disease, secondary to GTPCH1 deficiency it is clear that this is a distinct condition, clinically as well as biochemically and genetically. At the molecular level it has been shown to be due to a single gene defect causing sepiapterin reductase deficiency (SR IVS-II, 2G). The mutation of the second nucleotide in the second exon–intron junction is thought to impair transcription processing and diminish Sepiapterin messenger RNA levels (Farrugia *et al.*, 2005). Moderate cognitive impairment is not a feature of ADGTPCH1 deficiency or part of the classical clinical description of Segawa disease. However, cognitive impairment is a feature of several of the described conditions within the disorders of BH₄ metabolism, particularly systemic GTPCH1, and 6-pyruvoyl-tetrahydrobiopterin synthase and dihydropterin reductase deficiencies which show hyperphenylalaninaemia, and the cognitive impairment appears to be progressive without treatment and not totally prevented by treatment.

All patients with sepiapterin reductase deficiency have continued to make progress intellectually both before and after being treated, which does not suggest an active metabolic

Table 1 Summary of clinical features

Patient	Bulbar involvement	Early motor delay	Diurnal variation	Oculogyric crises	Dystonia	Hypotonia	Parkinsonian tremors	Chorea	Cognitive delay
1	+	+	+	+	+	+	–	+	+
2	+	+	+	+	+	+	–	+	+
3	–	+	+	+	+	+	–	+	+
4	+	+	+	+	–	–	–	–	+
5	–	+	+	+	+	–	–	+	+
6	–	+	+	–	–	+	+	–	+
7	–	+	?	+	+	+	+	–	+

The clinical findings in this group of patients are summarized above.

encephalopathy, but there is no evidence that L-dopa treatment had significant impact upon their cognitive progress. Specifically, the cognitive outcome in the earliest treated children (Patients 6 and 7) was no better than those who were treated much later. Although this might suggest a primary defect in brain development, more detailed longitudinal data on cognitive function are needed. It could also be important to screen for the condition at birth so that early treatment with L-dopa and possibly other metabolic interventions to restore CNS neurotransmitters could be used very early.

The motor features of dystonia with diurnal variation and a dramatic response to L-dopa are broadly shared with the

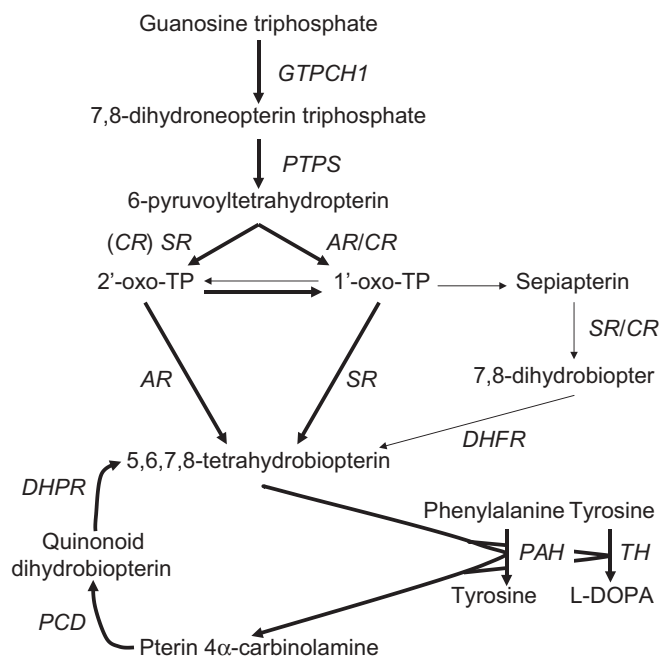


Fig. 1 Synthesis and regeneration of tetrahydrobiopterin. 2'-oxo-TP is 1'-hydroxy-2'-oxopropyltetrahydrobiopterin, 1'-oxo-TP 2'-hydroxy-1'-oxopropyltetrahydrobiopterin. Enzymes are shown as italics and *GTPCH1* is GTP cyclohydrolase I, *PTPS* is 6-pyruvoyltetrahydropterin synthase, *CR* carbonyl reductase, *SR* sepiapterin reductase, *AR* aldose reductase, *DHFR* dihydrofolate reductase, *DHPR* dihydropteridine reductase, *PAH* phenylalanine hydroxylase, *TH* tyrosine hydroxylase and *PCD* pterin 4 α -carbinolamine dehydratase.

GTPCH1 deficiency but there are clear differences to that phenotype. The congenital onset in all and an early predominance of hypotonia in a tetraplegic distribution with frequent bulbar involvement are not characteristic of GTPCH1 deficiency, although a very small number of recently described cases have been reported with these features (Robinson *et al.*, 1999; Tsirikos *et al.*, 2004). Such cases share with this new condition the likely early diagnosis of 'unexplained cerebral palsy' or perhaps better unexplained congenital motor disorder and add to the case for a trial of L-dopa in this situation, although the chances of a positive response outside people of Maltese origin may be very small. In no children was there clearly documented peripartem asphyxia with acute encephalopathy but two had meconium-stained liquor, which was of doubtful significance. The doses of L-dopa used were usually quite low (Table 2).

Early bulbar involvement is seen in several of the other disorders in this metabolic pathway. The Parkinsonian tremor seen in two is not a feature of ADGTPCH1 deficiency, but chorea particularly aggravated by L-dopa is sometimes observed. Oculogyric crises of early onset often combined with retrocollis, which seem very similar to that reported in post-encephalitic Parkinson's disease, were present in all but one and are only occasionally reported in ADGTPCH1 deficiency/Segawa disease. Oculogyric crises are also reported in several of the other conditions in this pathway and may be misdiagnosed as epilepsy. The type of diurnal variation in the ocular phenomena is interesting in that sleep was the only effective treatment before L-dopa was given, but that totally abolished the attacks. Relief of oculogyric crises by sleep occurs in the other conditions in this group of metabolic disorders.

Hyperprolactinaemia in Patient 2 is presumably caused by a central defect in dopamine delivery in analogy with similar side effects of anti-psychotic drugs that block dopamine D₂ receptors (Taylor, 2003).

The genetic and biochemical, and most of the clinical evidence support an autosomal recessive inheritance which contrasts with ADGTPCH1 deficiency. There were no definitely affected members of the previous generation though it will be important to investigate, wherever possible, those with motor or cognitive problems. It is also clear that this

Table 2. Medication details

Patient number	Date L-dopa started	Age L-dopa Started	Starting dose of L-dopa in mg/day and (mg/kg/day)	Dose of L-dopa on the day of assessment (March 28, 2001) in mg/day and (mg/kg/day)	Current (2004) dose of L-dopa in mg/day and (mg/kg/day)
1	November 97	7 years	50 (2.3)	100 (2.2)	150 (1.8)
2	February 98	10 years 10 months	50 (1.6)	100 (2)	150 (2.7)
3	January 98	8 years 2 months	50 (1.6)	100 (1.8)	150 (2)
4	February 98	5 years 3 months	25 (1.7)	37.5 (2)	100 (1.9)
5	June 00	4 years 2 months	25 (1.5)	50 (2.7)	50 (1.9)
6	August 00	7 months	12.5 (1.6)	100 (9.5)	100 (5.9)
7	May 99	1 years 1 months	50 (4)	75 (3.6)	100 (3.1)

is purely a CNS disorder. Details of the metabolic pathways involved are not yet fully agreed but are becoming reconciled through the reporting and investigation of further patients. The account presented here is a summary of the current position. SR plays a role solely in the synthesis of BH₄. However, there are two variants of this pathway. SR catalyses a two step reaction. The first step can also be catalysed by the enzyme aldose reductase.

Thus, in pathway 1, which is the physiological condition, SR catalyses both reactions to produce BH₄. However, in pathway 2, which is used in SR deficiency, aldose reductase catalyses the first step of the reaction and then the product enters the salvage pathway where finally dihydrofolate reductase catalyses the formation of BH₄. This happens in the liver, kidneys and all other peripheral tissues where BH₄ is synthesized. In the brain dihydrofolate reductase activity is very much lower (<10%), so the salvage pathway does not go to completion and there is accumulation of sepiapterin—a CSF marker for this disease (Zorzi *et al.*, 2002). No sepiapterin is formed in peripheral fluids because the salvage pathway goes to completion. This also explains why blood phenylalanine is never elevated, but dopamine and serotonin are always low. The peripheral functions of SR are compensated for, but the CNS ones are not and this leads to deficient production of 5,6,7,8-tetrahydrobiopterin and thus of dopamine. (See Fig. 1).

The finding of the new mutation in the SPR gene and not in the GTPCH1 gene clearly defines this as a distinct condition involving a complex motor disorder which is L-dopa responsive and cognitive impairment which is not responsive and confirms that sepiapterin reductase deficiency is a clinical disease. Until recently sepiapterin reductase deficiency was regarded as a defect for which there were natural compensatory mechanisms and worldwide there have been reports of only six patients with this deficiency. Two patients of Turkish origin have been described with similar features, retardation, dystonia, diurnal variation, tremor and oculogyric crises, good evidence of sepiapterin reductase deficiency with two different abnormalities in the gene and a response to L-dopa (Blau *et al.*, 1996, 2001; Bonafé *et al.*, 2001). The neurochemistry has been investigated by the demonstration of high CSF levels of sepiapterin in the two patients, but not of

xanthopterin and 3' hydroxysepiapterin (Zorzi *et al.*, 2002). This group contrasted these findings with the lack of sepiapterin in dihydropteridine reductase deficiency, in which there is also severe deficiency of BH₄. The uniformity of the gene defect in our patients suggests a founder effect.

References

- Blau N, Barnes I, Dhondt JL. International database of tetrahydrobiopterin deficiencies. *J Inher Metab Dis* 1996; 19: 8–14.
- Blau N, Thöny B, Cotton RGH, Hyland K. Disorders of tetrahydrobiopterin and related biogenic amines. In: Scriver CR, Beaudet AL, Sly WS, Valle D, Childs B, Vogelstein B, editors. *The metabolic and molecular bases of inherited disease*, 8th ed. New York: McGraw-Hill; 2001. p. 1725–76.
- Bonafé L, Thöny B, Penzien JM, Czarnecki B, Blau N. Mutations in the sepiapterin reductase gene cause a novel tetrahydrobiopterin-dependent monoamine-neurotransmitter deficiency without hyperphenylalaninemia. *Am J Hum Genet* 2001; 69: 269–77.
- Farrugia R, Scern CA, Montalto SA, Parascandolo R, Neville BGR, Felice A. Molecular pathology of tetrahydrobiopterin (BH₄) deficiency in the Maltese population (2005) In preparation.
- Ichinose H, Ohye T, Takahashi E, Seki N, Hori T, Segawa M, et al. Hereditary progressive dystonia with marked diurnal fluctuation caused by mutations in the GTP cyclohydrolase I gene. *Nat Gen* 1994; 8: 236–42.
- Lenicker HM, Vassallo Agius P, Young EP, Attard Mortalto SP. Infantile generalized GMI gangliosidosis: high incidence in the Maltese Islands. *J Inher Metab Dis* 1997; 20: 723–4.
- Marwan MM, Scerri CA, Zarroag SO, Cao A, Kyrri A, Kalogirou E, et al. Comparative in vivo expression of b+ thalassaemia alleles. *Hemoglobin* 1999; 3: 221–30.
- Robinson R, McCarthy GT, Bandmann O, Dobbie M, Surtees R, Wood NW. GTP cyclohydrolase deficiency; intrafamilial variation in clinical phenotype, including levodopa responsiveness. *J Neurol Neurosurg Psychiatry* 1999; 66: 86–9.
- Segawa M, Nomura Y, Nishiyama N. Autosomal dominant guanosine triphosphate cyclohydrolase I deficiency (Segawa disease). *Ann Neurol* 2003; 54 (Supp 6): S32–45.
- Segawa M, Hosaka A, Miyagawa F, Nomura Y, Imai H. Hereditary progressive dystonia with marked diurnal fluctuation. In: Eldridge R, Fahn S, editors. *Advances in Neurology*. New York: Raven Press; 1976. 14: p. 215–33.
- Taylor DM. Aripiprazole: a review of its pharmacology and clinical use. *Int J Clin Pract* 2003; 57: 49–54.
- Tsirikos AI, Carr LJ, Noordeen HH. Variability of clinical expression and evolution of spinal deformity in a family with late detection of dopa-responsive dystonia. *Dev Med Child Neurol* 2004; 46: 128–37.
- Zorzi G, Redweik U, Trippe H, Penzien JM, Thony B, Blau N. Detection of sepiapterin in CSF patients with sepiapterin reductase deficiency. *Mol Genet Metab* 2002; 75: 174–7.